

The Role of Inferior Parietal and Inferior Frontal Cortex in Working Memory

Juliana V. Baldo

Veterans Affairs Northern California Health Care System

Nina F. Dronkers

Veterans Affairs Northern California Health Care System and
University of California, Davis

Verbal working memory involves two major components: a phonological store that holds auditory–verbal information very briefly and an articulatory rehearsal process that allows that information to be refreshed and thus held longer in short-term memory (A. Baddeley, 1996, 2000; A. Baddeley & G. Hitch, 1974). In the current study, the authors tested two groups of patients who were chosen on the basis of their relatively focal lesions in the inferior parietal (IP) cortex or inferior frontal (IF) cortex. Patients were tested on a series of tasks that have been previously shown to tap phonological storage (span, auditory rhyming, and repetition) and articulatory rehearsal (visual rhyming and a 2-back task). As predicted, IP patients were disproportionately impaired on the span, rhyming, and repetition tasks and thus demonstrated a phonological storage deficit. IF patients, however, did not show impairment on these storage tasks but did exhibit impairment on the visual rhyming task, which requires articulatory rehearsal. These findings lend further support to the working memory model and provide evidence of the roles of IP and IF cortex in separable working memory processes.

Keywords: working memory, frontal cortex, parietal cortex, articulatory rehearsal, phonological storage

Short-term or working memory is a concept that has proven extremely useful in the analysis of both normal and impaired memory functioning (Baddeley & Hitch, 1974, 1994; Gathercole, 1994). This form of memory is characterized as a short-term store of information, allowing both maintenance and manipulation of information online. In this article, the terms short-term and working memory are used synonymously and distinct from long-term memory, a more permanent memory store. Also included in this category of working memory is immediate memory, which is often tested by span tasks (e.g., digit span). In Baddeley's model (Baddeley, 1996, 2000; Baddeley & Hitch, 1974), verbal working memory is divided into subsystems known as the phonological store and articulatory rehearsal. The phonological store is thought to be the locus of storage for auditory/verbal information, but this storage system can hold information for only a very short period of time. Articulatory rehearsal is a more active process thought to be responsible for the maintenance and refreshing of the information

held in the phonological store. A third component of the model is known as the "central executive," which is a more general, cross-modal mechanism involved in the allocation of attentional resources for both verbal and nonverbal processes. A fourth component was recently added to the model—the episodic buffer—to explain the influence of long-term (semantic) memory on working memory performance (Baddeley, 2000).

Baddeley's model has been particularly useful in the analysis of the neural underpinnings of working memory. For example, a number of functional neuroimaging studies have reported neural dissociations that are consistent with this cognitive model. Paulesu, Frith, and Frackowiak (1993) had normal participants perform two working memory tasks: a short-term letter recognition task (to tap the phonological store) and a letter rhyming judgment task (to tap articulatory rehearsal). Comparison of these experimental conditions with baseline conditions revealed a network of regions, including Broca's area (Brodmann's Area 44), superior temporal cortex (22/42), and supramarginal gyrus (SM). Both of the experimental tasks engaged Broca's area, but left SM activity was most associated with the recognition task. They concluded that the SM subserves the phonological store and that Broca's area subserves articulatory rehearsal. In another positron emission tomography study of verbal working memory, Awh, Smith, and Jonides (1995) had normal participants engage in a letter short-term recognition memory task as well as a two-back (letter) working memory task. Both of these verbal working memory tasks revealed significant activations, including left SM, Broca's area, and supplementary motor area. Importantly, comparison of the two-back task with a rehearsal condition reduced the Broca's area activation (but not SM activation), further supporting the idea that Broca's area mediates rehearsal. Thus, they, too, concluded that the short-term phonological store is located in the left SM (Brodmann's Area 40), whereas subvocal rehearsal is mediated by Broca's area (Brodmann's Areas 44 and 45 in the left hemisphere).

Juliana V. Baldo, Center for Aphasia and Related Disorders, Veterans Affairs Northern California Health Care System, Martinez, California; Nina F. Dronkers, Center for Aphasia and Related Disorders, Veterans Affairs Northern California Health Care System, and Departments of Linguistics and Neurology, University of California, Davis.

This research was supported in part by National Institutes of Health/National Institute of Neurological Disorders and Stroke Grant 5 P01 NS040813-2, National Institutes of Health/National Institute on Deafness and Other Communication Disorders Grant 5 R01 DC00216-20, and a National Institutes of Health National Research Service Award to Juliana V. Baldo. We thank Carl Ludy, Brenda Redfern, and David Wilkins for their contributions to this project.

Correspondence concerning this article should be addressed to Juliana V. Baldo, Center for Aphasia and Related Disorders, Veterans Affairs Northern California Health Care System, 150 Muir Road (126s), Martinez, CA 94553. E-mail: juliana@ebire.org

Other functional neuroimaging studies have also reported results consistent with this dissociation (e.g., Henson, Burgess, & Frith, 2000; Honey, Bullmore, & Sharma, 2000; Jonides et al., 1998; Salmon et al., 1996; however, see Chein & Fiez, 2001; Gruber, 2001). However, there is some discrepancy as to the exact location of the phonological store within parietal cortex, as some studies have reported more ventral portions of inferior parietal (IP), whereas other studies have reported more dorsal portions of IP (Becker, MacAndrew, & Fiez, 1999).

Baddeley's working memory model has also been applied to the understanding of working memory deficits in neurologic patients, although the focus has been primarily on cognitive dissociations rather than on anatomical ones (Gathercole, 1994; Martin & Saffran, 1997). For example, some patients have been reported to exhibit a selective impairment in the phonological store, as evidenced by a reduced auditory-verbal memory span with relatively preserved speech output (e.g., Saffran & Martin, 1990; Vallar & Baddeley, 1984). These patients also have shown a reduced phonological similarity effect, an effect observed in normal participants in which memory span for phonologically distinct words (e.g., cat, tape, pool, car) is better than that for phonologically similar words (e.g., cat, back, lap, gal). One such patient, Baddeley's patient PV, had a large perisylvian lesion in the left hemisphere, which thus did not allow for specific localization of the phonological store (Vallar & Baddeley, 1984). Saffran and Martin (1990) tested similar patients who exhibited severely reduced memory spans and a reduced recency effect in verbal learning. These patients had more localized lesions: a left temporo-parietal plus right inferior frontal (IF) lesion (patient TI) and a left middle/superior temporal lesion (patient CN). Vallar, Di Betta, and Silveri (1997) reported a male patient with a left temporo-parietal injury due to surgical excision following a severe head injury. He showed a pattern of impaired phonological storage with somewhat preserved rehearsal, on the basis of his performance on short-term memory and verbal learning tasks.

Predating Baddeley's model, Shallice, Warrington, and colleagues reported a number of patients with severely reduced auditory-verbal short-term memory (Shallice & Warrington, 1977; Warrington, Logue, & Pratt, 1971; Warrington & Shallice, 1969). They showed that this deficit was not due simply to output deficits, as some patients exhibited normal spontaneous speech. Also, working memory performance did not improve with nonverbal response modalities, such as pointing or recognition procedures. One of these patients, KF, had a severe head injury that resulted in damage to the left posterior cortex that included the supramarginal and angular gyri. Another patient (JB) had normal spontaneous speech but significantly reduced letter, word, and digit spans (2.5–3.4 items) due to a tumor removal in the vicinity of the left angular gyrus (also reported in Shallice & Butterworth's, 1977, study). Thus, a number of case studies have been generally consistent with the localization of the phonological store to posterior brain regions; however, these patients were recruited on the basis of behavior, not anatomy, and thus this association has not been validated.

Although a number of patient studies have focused on the phonological store, few studies have reported patients with a selective deficit in articulatory rehearsal (Vallar et al., 1997). Belleville, Peretz, and Arguin (1992) tested a patient (RoL) who had a reduced span for verbal material, showed evidence of a

phonological similarity effect in the auditory domain, and performed normally on a dual task paradigm. Belleville et al. concluded that RoL's pattern of deficits and intact abilities were evidence of a selective deficit in articulatory rehearsal, with a preserved phonological store and central executive. RoL's lesion was in left temporoparietal cortex, a finding that is not consistent with the association of articulatory rehearsal with IF cortex, as suggested by neuroimaging studies. Vallar et al. (1997) tested two patients, one of whom had an impairment in articulatory rehearsal with a relatively preserved phonological store. This patient's lesion was due to a stroke that involved left premotor and rolandic regions as well as the anterior insula. In this case, the anatomical-behavioral pattern was somewhat consistent with prior neuroimaging findings of anterior regions being associated with articulatory rehearsal; however, this patient's lesion was not localized in Broca's area/IF gyrus, as would be predicted from neuroimaging. Last, a meta-analysis of delayed response performance found that verbal rehearsal/manipulation was affected by prefrontal cortex lesions, whereas span performance was not, consistent with functional neuroimaging findings (D'Esposito & Postle, 1999).

In the current study, we were interested in characterizing verbal working memory deficits in anatomically-defined patient groups chosen on the basis of relatively focal lesions. This anatomical focus is distinct from previous working memory studies that have traditionally selected patients on the basis of their behavioral profile (e.g., Shallice & Vallar, 1990). Two groups of patients were selected from our research database on the basis of anatomy: one group with lesions in left IP cortex and a second group with left IF lesions that involved Broca's area. Patients were tested on a series of tasks that have been used previously to test phonological storage and articulatory rehearsal (see Vallar & Papagno, 2002) to further study the relative contributions of these two brain regions with respect to their role in verbal working memory. To our knowledge, this is the first patient study to directly compare these two anatomically-defined patient groups on the same working memory tasks. On the basis of the predominance of findings in the literature, performance on tasks that taxed the phonological store (verbal span, auditory rhyming, and repetition) was predicted to be selectively impaired in the IP patients. Tasks that engaged articulatory rehearsal in addition to phonological storage (visual rhyming and a two-back task) were expected to reveal impairment in IF patients as well as IP patients. To be clear, the current study did not allow for a true double dissociation between IP and IF patients because tasks used to test articulatory rehearsal also engage the phonological store. Thus, IP patients were predicted to be most impaired on storage tasks, whereas IP and IF patients were predicted to be similarly impaired on rehearsal tasks.

Method

Participants

A total of 10 patients with lesions in the left IP cortex (8 men and 2 women), 8 patients with lesions in the left IF cortex (6 men and 2 women), and 6 normal controls (5 men and 1 woman) participated in the current study (see participant characterization in Table 1). The three groups did not differ in terms of age, $F(2, 21) = 1.55, p = .24$, or education, $F(2, 21) = 0.18, p = .84$. All participants reported being right-handed on a handedness inventory, although one of the IF patients reported doing some activities with her left hand premonitory. Inclusionary criteria for both

Table 1
Participant Characterization

Participant	Lesion site ^a	Gender	Age at test (years)	Education (years)	Aphasia type	Months post-onset	Volume (cc)	Tasks completed
0629	IF	M	64	8	WNL	143	14.8	span, rep
0676	IF	M	67	15	WNL	13	25.5	span, rep, AR, VR, 2B
0698	IF	M	63	17	anomic	117	106.4	span, rep, VR
0983	IF	W	58	14	anomic	35	79.1	span, rep
0743	IF	M	53	11	anomic	32	31.2	span, rep, AR, VR, 2B
0925	IF	W	56	11	anomic	63	89.2	span, rep
0683	IF	M	65	12	WNL	13	39.8	span, rep, AR, VR, 2B
1088	IF	M	42	18	unclassifiable	36	—	span, rep, AR, VR, 2B
0694	IP	M	48	14	CA	14	92.0	span, rep
0736	IP	M	73	16	CA	31	39.3	span, rep, AR, VR, 2B
0822	IP	M	73	12	CA	13	17.3	span, rep, AR, VR, 2B
0626	IP	M	61	10	CA	41	71.4	span, rep, VR
0948	IP	M	68	15	CA	10	54.2	span, rep, AR, 2B
0896	IP	M	58	16	WNL	115	53.8	spanrep, AR, VR, 2B
0661	IP	W	63	12	anomic	22	73.5	span, rep
0756	IP	M	65	10	WNL	118	—	span, rep
0820	IP	W	65	5	CA	14	124.9	span, rep
1063	IP	M	58	14	CA	24	—	span, rep, AR, VR, 2B

Note. Dashes signify data are not available. IF = inferior frontal; M = man; WNL = within normal limits; rep = repetition tasks; AR = auditory rhyming task; VR = visual rhyming task; 2B = two-back task; W = woman; IP = inferior parietal; CA = conduction aphasia.

^aThe means for the IF participants (6 men, 2 women) are as follows: age at test = 58.5 years; education = 13.2 years; months postonset = 56.5; volume (cc) = 55.1. The means for the IP participants (8 men, 2 women) are as follows: age at test = 63.2 years; education = 12.4 years; months postonset = 40.2; volume (cc) = 65.8. The means for the control participants (5 men, 1 woman) are as follows: age at test = 65.2 years; education = 12.7 years.

patients and controls included (a) native English speaking, (b) being between the ages of 30 and 80 years, and (c) having no prior history of psychiatric illness, dementia, neurologic illness, or drug/alcohol abuse.

Patients were selected from our large database of stroke patients and/or were recruited from the Veterans Affairs Medical Center, Martinez, California. They were chosen on the basis of the presence of a relatively focal lesion that involved either IP or IF cortex and were excluded if their lesions extended significantly beyond parietal or frontal cortex, respectively. For the purposes of this article, IP was defined as Brodmann's Areas 39 and/or 40, and IF was defined as Brodmann's Areas 44 and/or 45. Figure 1 shows that patients' maximal lesion overlap was in these regions, although some patients had lesions that extended beyond these areas. Patients all suffered from a single cerebrovascular accident in the territory of the left middle cerebral artery (i.e., all due to stroke and not tumor or traumatic brain injury). Patients' lesions were reconstructed with MRICro software (Rorden & Brett, 2000) on the basis of computed tomography/magnetic resonance imaging scans and were verified by a board-certified

neurologist. Lesion size (in cc) did not differ between the two patient groups, $t(13) = 0.36, p = .56$. Testing occurred at least 10 months postonset of stroke. IP and IF patients did not differ in terms of the number of months poststroke onset, $t(16) = 0.31, p = .58$. Because of attrition, not all patients were available for testing on all measures (see Table 1 for details).

All testing was completed at the Veterans Affairs Northern California Health Care System in Martinez, California. The study was approved by the Institutional Review Board, and all participants read and signed consent forms prior to participation.

Materials and Procedures

Language assessment. Patients' speech and language were assessed with the Western Aphasia Battery (WAB; Kertesz, 1982). Patients' clinical diagnoses (aphasia types) according to the WAB are presented in Table 1. Some patients in each group tested within normal limits on the battery

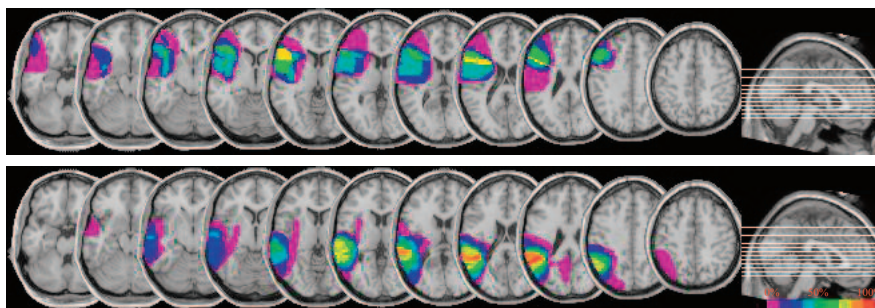


Figure 1. Lesion reconstructions of inferior frontal patients (top) and inferior parietal patients (bottom). The percentage of lesion overlap (from 0% to 100%) is indicated by the color bar, with colors closer to red indicating greater overlap.

(score > 93.8), whereas others had aphasic symptoms, including anomia and dysfluency. On the basis of the WAB, the IF and IP groups were matched in terms of their level of spontaneous speech (fluency), $t(16) = 1.06, p = .31$, and comprehension, $t(16) = 0.49, p = .63$, so that these would not be factors in differential performance on the working memory measures (see Figure 2). All patients scored between 75%–100% performance on spontaneous speech (IP, $M = 87%$; IF, $M = 91%$) and 82%–100% performance on comprehension (IP, $M = 92%$; IF, $M = 94%$).

Span tasks. Patients and controls were tested on a series of span tasks: spatial span, word span, digit span with a verbal response, and digit span with a pointing response. In the spatial span task, participants were instructed to point to a series of blocks in an array in the same order as the examiner (i.e., Corsi span test). The first trial consisted of a sequence of two locations, and the subsequent trials consisted of sequences of increasing length (sequences of three, four, etc.). If the examinee failed a trial, then a second trial of the same length was given but with a novel sequence. Testing was discontinued after an examinee failed two trials of the same length. Spatial span was determined by the longest sequence obtained by the examinee.

In the word span task, participants were asked to repeat words spoken by the examiner at the rate of approximately one word per second. The word sequences started with a span of one word and increased until the participant failed two trials at the same span. The digit span tasks were administered in a similar fashion, except that participants heard a series of digits spoken by the examiner. In the verbal digit span task, they had to repeat the series out loud. In the pointing digit span task, participants repeated the series that they heard by pointing on a number line that consisted of the digits 1–9 printed in black ink. Testing was discontinued after an examinee failed two trials of the same length. Span was determined by the longest sequence obtained by the examinee.

Repetition tasks. Participants were administered an in-house measure called the Martinez Repetition Scale that tested their ability to repeat single

words, nonwords, and sentences. Words (concrete nouns) and pronounceable nonwords (e.g., dakimapon) of increasing syllable length were presented, and participants were asked to repeat the items just as the examiner said them. If they failed a particular item, then participants were given another item of the same syllable length, and the test was discontinued after two failures at the same length.

Participants were also asked to repeat sentences read by the examiner. The first sentence item was only one word long (e.g., *Eat*), with subsequent sentences increasing in length in terms of the number of words in the sentence (e.g., *Cows walk*). Testing continued until a participant was unable to repeat two different sentences of the same length. Again, performance was scored as the longest item repeated correctly.

Rhyming tasks. Participants performed rhyme judgment tasks in both the auditory and visual domains. Word stimuli for the tasks were generated with the Machine Readable Dictionary database (Wilson, 1988). The stimuli were common, single syllable words with a Kucera–Francis written frequency of greater than or equal to ten. The stimuli included both concrete and abstract words as well as nouns, verbs, and adjectives. The rhyming tasks were programmed on a Macintosh computer.

In the visual rhyming task, there were 60 orthographically related rhyme pairs (e.g., *mold* . . . *told*) and 60 nonorthographically related rhyme pairs (e.g., *heart* . . . *part*). There were also 120 nonrhyming word pairs that served as catch trials (e.g., *cast* . . . *snow*). On a given trial, these paired word stimuli were presented sequentially in black lowercase for 1,000 ms with a blank interstimulus interval (ISI) of either 500, 1,000, or 2,000 ms between words. Participants were instructed to press the space bar if the second word rhymed with the first word presented and to do nothing if the words did not rhyme. Both accuracy and reaction time on rhyming word pairs were recorded.

In the auditory rhyming condition, the task was similar except that the stimuli were presented in stereo through speakers attached to the computer. The same word stimuli and ISIs were used; however, in this task, the

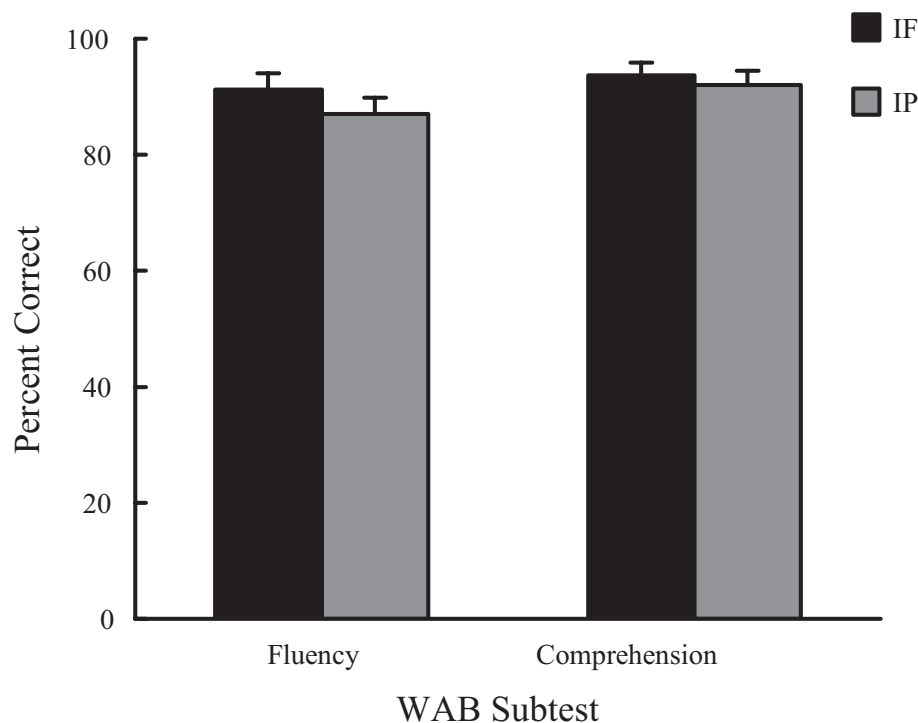


Figure 2. Fluency and comprehension performance on the Western Aphasia Battery (WAB) in inferior frontal (IF) and inferior parietal (IP) patients.

orthographic–nonorthographic distinction was not relevant because the words were presented auditorily. Auditory and visual rhyming tasks were administered in separate sessions. Practice trials were first administered to introduce each task, and these trials were repeated when necessary to ensure that participants understood the instructions. Following practice, participants were administered all trials in one continuous block of 240 trials, and the program was paused if the participant needed to take a break.

Two-back task. Participants were administered a two-back working memory task in which they had to indicate when a word was the same as the word that appeared two words previously. Words were presented in black lowercase on an iMac computer for 1,500 ms in a serial fashion with a 2,500-ms ISI. Participants had 2,500 ms to respond by pressing the spacebar if the word was the same as the one that appeared two words before and were instructed to just wait for the next word if they thought it was different. There were two blocks of 60 words each: 15 targets and 45 catch trials. Some of the catch trials were words that were repeated in the one-back, three-back, and four-back positions so that the target could not be discerned simply by virtue of it being a repeated item.

Results

Span Performance

Data from the span tasks were analyzed with separate one-way analyses of variance (ANOVAs) to compare group (IP, IF, or control). The dependent variable (DV) was the longest sequence of items repeated correctly (i.e., span). Data are shown in Figure 3. For digit span, the overall ANOVA was significant, $F(2, 21) = 11.36, p < .001$. As predicted, IP patients ($M = 3.4, SD = 0.7$) performed significantly worse than IF patients ($M = 5.4, SD = 1.6$; Tukey's honestly significant difference [HSD], $p = .009$) and controls ($M = 6.3, SD = 1.0$; Tukey's HSD, $p = .001$), whereas IF patients and controls did not differ (Tukey's HSD, $p = .36$). Importantly, the same pattern of performance occurred with digit span, even when a pointing response was used, $F(2, 17) = 24.36, p < .001$, with IP patients ($M = 2.3, SD = 1.5$) performing below the level of IF patients ($M = 5.3, SD = 0.8$; Tukey's HSD, $p = .001$) and controls ($M = 7.0, SD = 1.1$;

Tukey's HSD, $p < .001$). Again, IF patients and controls did not differ significantly (Tukey's HSD, $p = .065$).

Results from the word span task also showed a significant group difference, $F(2, 21) = 11.29, p < .001$. IP patients ($M = 2.7, SD = 0.9$) showed a significant impairment relative to IF patients ($M = 4.2, SD = 0.9$; Tukey's HSD, $p = .003$) and elderly controls ($M = 4.5, SD = 0.5$; Tukey's HSD, $p = .001$). IF patients and controls did not differ on word span (Tukey's HSD, $p = .85$).

We also tested spatial span to evaluate claims that IP may be modality general, rather than being specialized for auditory–verbal storage. The overall ANOVA was significant, $F(2, 15) = 9.54, p < .01$. Again, IP patients ($M = 4.0, SD = 0.0$) performed significantly worse than both IF patients ($M = 5.0, SD = 0.9$; Tukey's HSD, $p = .03$) and controls ($M = 5.5, SD = 0.5$; Tukey's HSD, $p = .002$), whereas IF patients and controls did not differ (Tukey's HSD, $p = .35$). Thus, as predicted, span performance was affected in IP but not IF patients whether the response modality was oral or pointing.

Repetition Performance

Performance on word, nonword, and sentence repetition was analyzed in a similar way to span performance. In the case of word and nonword repetition, the DV was the length of the word/nonword (in number of syllables). In the sentence repetition task, the DV was the length of the sentence (in number of words). These data are shown in Figure 4.

A one-way ANOVA revealed significant group differences for word repetition, $F(2, 21) = 5.62, p < .05$. As predicted, IP patients ($M = 4.5, SD = 1.6$) performed significantly worse than IF patients ($M = 6.0, SD = 0.0$; Tukey's HSD, $p = .02$) and controls ($M = 6.0, SD = 0.0$; Tukey's HSD, $p = .04$), whereas IF patients and controls did not differ (Tukey's HSD, $p = 1.0$). A similar pattern was observed for nonwords, $F(2, 21) = 22.24, p < .001$, as IP patients ($M = 2.8, SD = 1.4$) performed poorly relative to IF

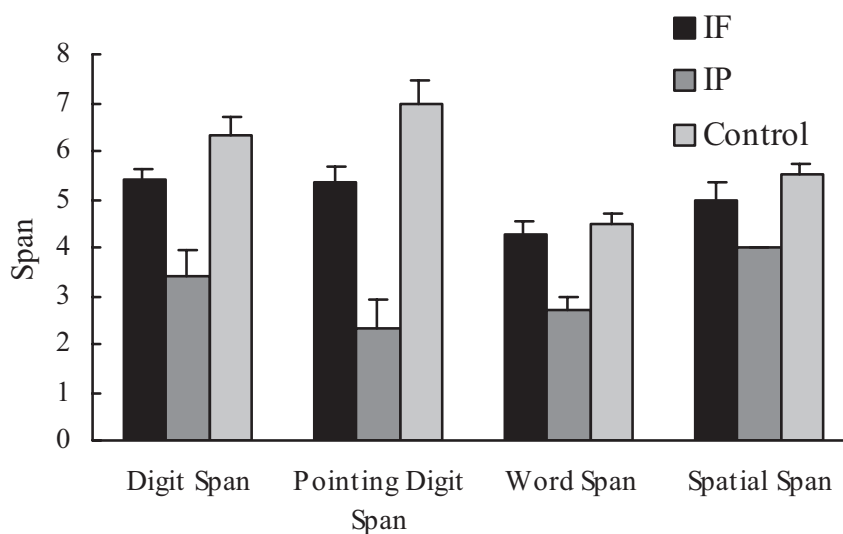


Figure 3. Verbal and nonverbal span performance in patients and controls. IF = inferior frontal; IP = inferior parietal.

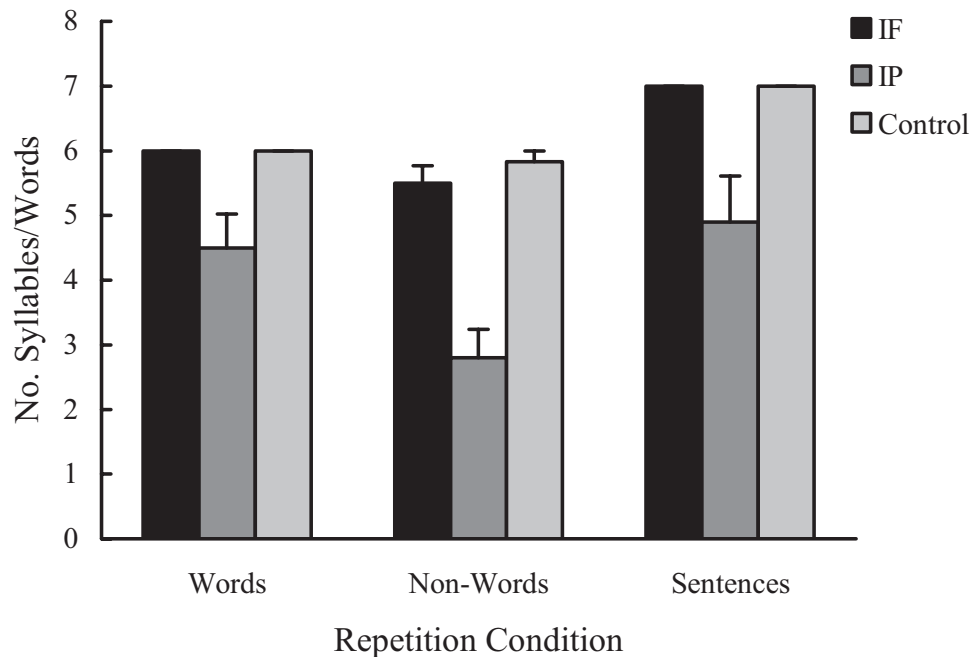


Figure 4. Repetition performance for words, nonwords, and sentences. IF = inferior frontal; IP = inferior parietal.

patients ($M = 5.5$, $SD = 0.8$; Tukey's HSD, $p < .001$) and controls ($M = 5.8$, $SD = 0.4$; Tukey's HSD, $p < .001$). IF patients and controls did not differ on nonword repetition (Tukey's HSD, $p = .82$).

Last, sentence repetition also distinguished the groups, $F(2, 21) = 6.02$, $p < .01$. Again, IP patients ($M = 4.9$, $SD = 2.2$) were significantly impaired at repeating sentences compared with IF patients ($M = 7.0$, $SD = 0.0$; Tukey's HSD, $p = .02$) and controls ($M = 7.0$, $SD = 0.0$; Tukey's HSD, $p = .03$), whereas IF patients and controls did not differ (Tukey's HSD, $p = 1.0$).

As with span performance, repetition performance was most impaired in IP patients, as predicted. This impairment was most striking for nonwords, the implications of which are addressed in the Discussion section.

Rhyming Performance

Data from the auditory and visual rhyming tasks were analyzed with separate ANOVAs, and results are shown in Figures 5 and 6. The DV was accuracy calculated as d' , which factors in both hits and false alarm rates. A larger d' signifies better accuracy. Reaction times were not analyzed because they were only available for target trials and because patients' reaction times were highly variable. One IF patient (0925) was excluded from both rhyming analyses because her performance was at chance (greater than two standard deviations from the group mean).

Auditory rhyming performance was analyzed with a mixed 3×3 ANOVA, with group (IP, IF, or control) as a between-subjects variable and ISI (500 ms, 1,000 ms, or 2,000 ms) as a within-subjects variable. The effect of group was statistically significant, $F(2, 12) = 4.32$, $p < .05$ (see Figure 5). As predicted, IP patients ($M = 3.5$, $SE = 0.7$) performed significantly worse overall

on the auditory rhyming task relative to controls ($M = 6.5$, $SE = 0.7$; Tukey's HSD, $p = .03$). IF patients ($M = 4.9$, $SD = 0.8$) and controls did not differ (Tukey's HSD, $p = .37$). The effect of ISI was not significant, $F(2, 24) = 2.21$, $p = .13$, nor was the Group \times ISI interaction, $F(4, 24) = 0.28$, $p = .89$.

Data from the visual rhyming task were analyzed with a mixed $3 \times 2 \times 3$ ANOVA, with group (IP, IF, or control) as a between-subjects variable, and condition (orthographic, nonorthographic trials) and ISI (500 ms, 1,000 ms, or 2,000 ms) as within-subjects variables. There was a significant main effect of group, $F(1, 13) = 19.04$, $p < .001$. As predicted, both IP ($M = 2.8$, $SE = 0.6$) and IF patients ($M = 3.5$, $SE = 0.6$) were less accurate overall at making visual rhyme judgments relative to controls ($M = 7.7$, $SE = 0.6$; Tukey's HSD, both $ps < .001$; see Figure 6). There was also a main effect of condition, as accuracy was greater overall on orthographic trials (i.e., trials in which the rhyme pairs were spelled similarly), $F(1, 13) = 7.84$, $p < .05$. There was no effect of ISI, $F(2, 26) = 2.52$, $p = .10$, and none of the interactions approached significance. Thus, as predicted, IP patients were impaired on auditory rhyming relative to controls because of its reliance on the phonological store, whereas both IP and IF patients were impaired on visual rhyming because of its additional reliance on articulatory rehearsal.

Two-Back Performance

Data from the two-back task were analyzed with a one-way ANOVA evaluating Group (IP, IF, or control), and the DV was accuracy, calculated as d' . The overall ANOVA was significant, $F(2, 12) = 4.47$, $p < .05$. Consistent with prediction, IP patients ($M = 1.3$, $SD = 0.7$) were impaired relative to controls ($M = 4.2$, $SD = 2.2$; Tukey's HSD, $p = .04$), and IP and IF patients did not

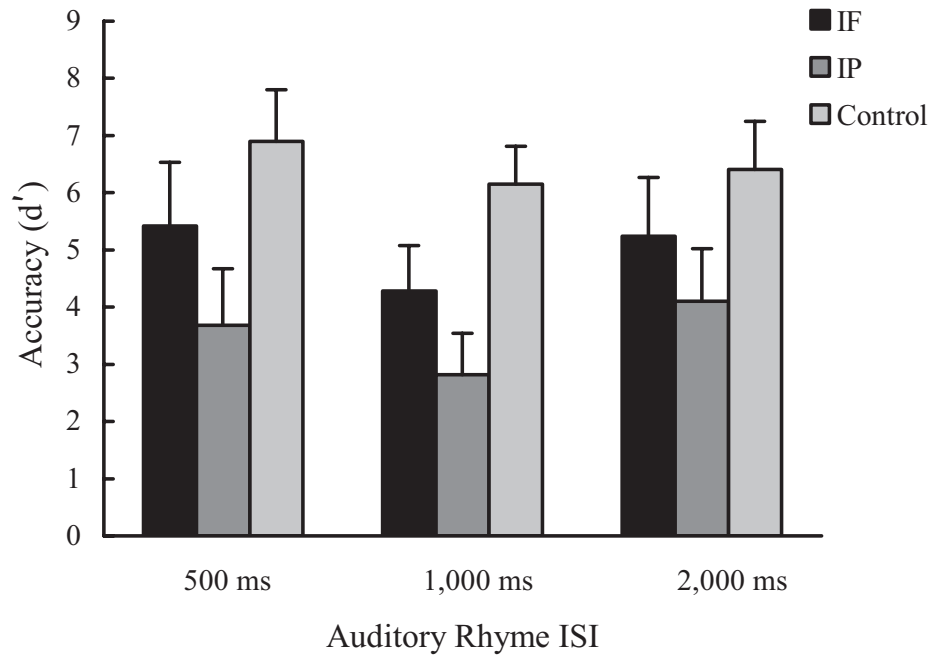


Figure 5. Auditory rhyme performance in patients and controls at three different interstimulus intervals (ISIs). IF = inferior frontal; IP = inferior parietal.

differ from each (Tukey's HSD, $p = .83$; see Figure 7). Counter to prediction, IF patients ($M = 2.0$, $SD = 0.2$) did not differ significantly from controls (Tukey's HSD, $p = .14$).

On two-back working memory—a task that engages both the

phonological store and rehearsal—IP and IF patients exhibited similarly poor accuracy as was predicted, but only the IP patients differed significantly from controls. Reasons for this are explored further below.

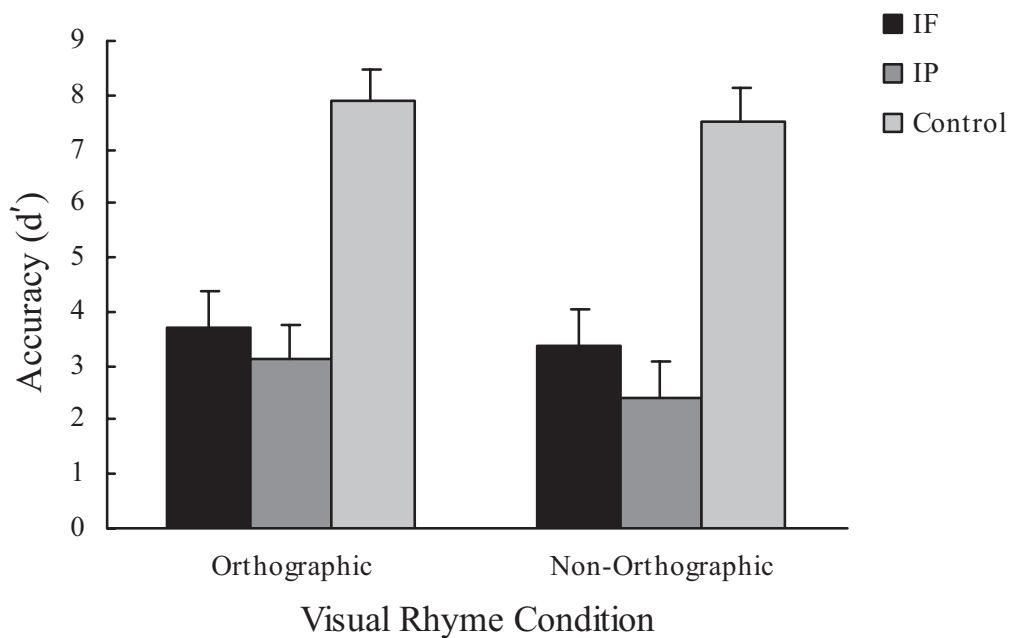


Figure 6. Visual rhyme performance in patients and controls for orthographically related and nonorthographic rhyme pairs. IF = inferior frontal; IP = inferior parietal.

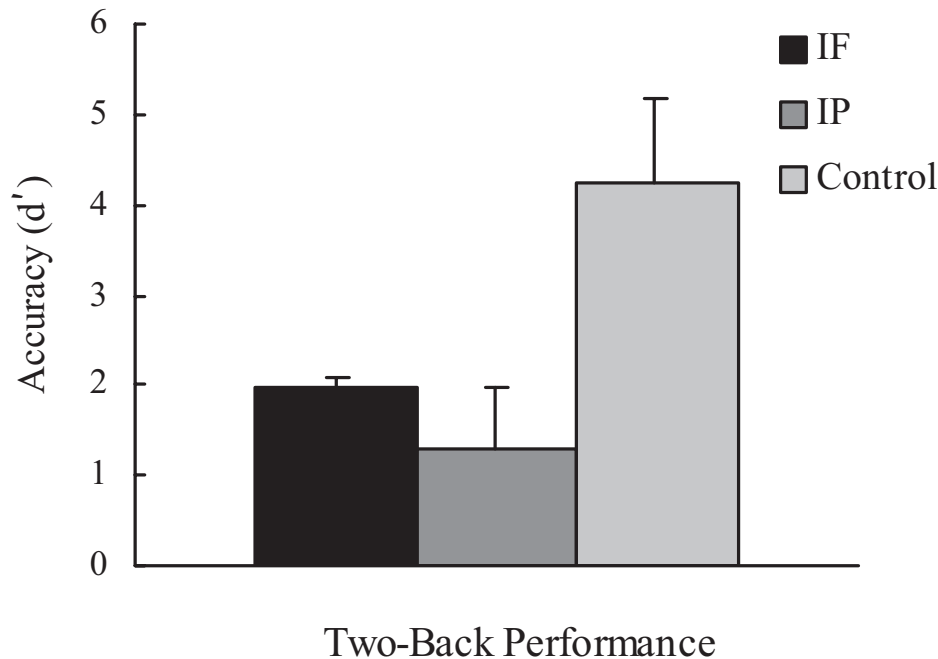


Figure 7. Performance on a two-back working memory task in patients and controls. IF = inferior frontal; IP = inferior parietal.

Discussion

In the current study, patients with focal lesions involving either IP or IF cortex were tested on a series of working memory tasks designed to tap the phonological store (span, repetition, auditory rhyming) and articulatory rehearsal (visual rhyming, two-back task). It was predicted that IP patients would be disproportionately impaired on the phonological tasks and that IF patients would only show disruption once rehearsal was required. The current findings generally supported these predictions. Specifically, IP patients were selectively impaired in their ability to repeat words, sentences, and digits. These data suggest that the short-term phonological representation is degraded in IP patients. This deficit was not due solely to difficulty in output, as IP patients were impaired even when they were allowed to use a pointing response. IP patients were also selectively impaired on an auditory rhyming task in which they had to decide whether two auditorily presented words rhymed, again reflecting a storage deficit. In contrast, patients with IF lesions did not differ from controls on span, repetition, and auditory rhyming tasks but were impaired on a visual rhyming task. This pattern is consistent with a selective deficit in articulatory rehearsal. Last, it was predicted that both IP and IF patients would be impaired on a two-back working memory task, which should engage both the phonological store and rehearsal. Although the pattern of performance was consistent with this prediction, only IP patients differed significantly from controls on this task.

The current findings complement earlier case studies of working memory in neurologic patients (e.g., Belleville et al., 1992; Shallice & Warrington, 1977; Vallar & Baddeley, 1984; Warrington et al., 1971; Warrington & Shallice, 1969). These studies have provided empirical support for Baddeley's working memory model, as

patients were shown to exhibit selective deficits in processes, such as phonological storage and articulatory rehearsal. Such studies traditionally have selected patients for study on the basis of behavioral criteria, such as the presence of short-term memory deficits, to characterize cognitive dissociations in working memory (Shallice & Vallar, 1990). In contrast, the current study identified patient groups on the basis of anatomical criteria, namely, focal lesions that involved either IP or IF cortex. In this way, we were able to systematically demonstrate the role of these regions in phonological storage and articulatory rehearsal, respectively.

Our findings are generally consistent with previous functional neuroimaging studies that have reported similar networks underlying working memory, namely, parietal regions and anterior, usually IF, regions (Hickok, Buchsbaum, Humphries, & Muftuler, 2003; Honey et al., 2000; Jonides et al., 1998; Paulesu et al., 1993; Postle, Berger, & D'Esposito, 1999; Salmon et al., 1996). By showing that patients with focal lesions in these regions have specific working memory deficits, our results suggest that these regions are not just involved in a large network but are crucial for the execution of working memory tasks. Moreover, we observed these deficits in a group of patients, rather than single case studies, with a sample size comparable with that used in functional neuroimaging studies.

An issue that has been raised in the neuroimaging literature is whether parietal cortex is modality specific, mediating auditory-verbal storage, or whether it is modality general (Chein, Ravizza, & Fiez, 2003). In the current group of patients, we also tested spatial span and found that IP patients were impaired on this task relative to frontal patients and controls. These data support the modality-general hypothesis, as both verbal and spatial spans were impaired in IP patients. It is also possible, however, that covert

verbal strategies are engaged during both tasks. This is particularly likely in the current study because the spatial locations were fixed and consistent across trials, and thus patients who were able could have developed a “verbal” strategy for recalling the spatial sequences (e.g., “top right, down left, middle right”). IP patients with storage deficits would be at a disadvantage for using such a strategy.

Another discrepancy in the neuroimaging literature has been the exact locus of verbal working memory within parietal cortex (Becker et al., 1999; Ravizza, Delgado, Chein, Becker, & Fiez, 2004). On the basis of functional magnetic resonance imaging findings, Ravizza et al. (2004) have suggested that there are distinct functional regions in IP cortex, with more ventral IP cortex playing a role in phonological encoding/recoding, and dorsal IP cortex playing a larger role in cognitive control aspects of working memory. In the current study, patients were chosen on the basis of having lesions in the supramarginal and/or angular gyri (Brodmann’s Areas 40 and 39, respectively), and the common area of infarct in this patient group was ventral, not dorsal, IP cortex. This group showed profound phonological storage deficits, suggesting that this region of IP is a critical zone for this component of working memory.

Although a number of tasks in the current study were sensitive to IP lesions, only visual rhyming evidenced significant impairment in IF patients relative to controls. This effect was predicted because visual rhyming, unlike auditory rhyming, requires intact articulatory rehearsal to convert the visual stimulus to a phonological form. However, it was also predicted that IF patients would be impaired relative to controls on a two-back working memory task because this task also engages rehearsal mechanisms. This effect did not reach statistical significance, although the pattern of performance was consistent with prediction. The failure to observe this effect is likely due to the large variability in the control group, whose accuracy varied widely on this task, with d' ranging from 2.5 to 8.6. The source of this variability is unclear.

In addition to the phonological store and articulatory rehearsal, Baddeley’s verbal working memory model also includes processes known as the central executive and, more recently, the episodic buffer. Previous work from our lab as well as others has shown that central executive processes are disrupted by lesions to dorsal portions of lateral prefrontal cortex (Baldo & Shimamura, 2000). For example, more attentional aspects of working memory are disrupted in patients with lesions restricted to this region (Baldo & Shimamura, 2000; Chao & Knight, 1995). Two of the IF patients in the current study had lesions that extended more dorsally, so we cannot rule out the possibility that this played a role in those particular patients.

The current study also did not directly test the role of the episodic buffer, a process recently added to Baddeley’s model, to explain the influence of long-term/semantic memory on the contents of working memory (Baddeley, 2000). Ongoing work from our lab speaks to this issue. Some of our patients with reduced working memory spans show a preserved ability for retaining the semantic “gist” of a given stimulus. We have observed this phenomenon in our patients with IP lesions on the WAB repetition subtest, as they will get the gist of an item but will not be able to repeat it verbatim (e.g., *The pastry chef was elated* was repeated by one patient as *Something about a happy baker*; Dronkers, Redfern, & Ludy, 1998). It is likely that this effect stems from the fact that

IP patients are unable to rely completely on their phonological store for immediate recall and thus use an alternate semantic route that normal individuals would only engage in long-term retrieval after the trace has long since faded (Baddeley, 1996). We have also found evidence of this gist effect even when IP patients do not respond verbally but simply have to choose between a target and a semantically related foil (Baldo & Dronkers, 2006). This role of semantics in working memory was also observed in the current study, as IP patients were especially poor at nonword repetition, which necessarily relies purely on the phonological form because no semantic associates are activated.

The working memory deficits observed in the current study have implications for comprehension performance in IP and IF patients. Previous studies have suggested an intimate link between working memory capacity and comprehension (Vallar & Papagno, 2002). As Vallar and Papagno (2002) have suggested, sentence comprehension may be deficient in patients with poor phonological memory when “the linear arrangement of words provides crucial information and lexical-semantic analyses do not constrain meaning” (p. 263). Consistent with this notion, data from our lab show that IP and IF patients are almost at ceiling for comprehension of simple syntactic structures, such as simple declaratives and possession, but their performance drops off precipitously for sentences with more complex structures, such as negative passives (Baldo, Wilkins, & Dronkers, 2006; Dronkers, Wilkins, Van Valin, Redfern, & Jaeger, 2004).

In short, the present study lends support to Baddeley’s working memory model, as we were able to show a distinction between phonological storage and articulatory rehearsal performance in two anatomically defined patient groups with lesions involving either IP cortex or IF cortex, respectively. A number of issues still remain, such as the extent to which these brain regions are modality specific as well as the role of a semantic route or the “episodic buffer” in working memory performance.

References

- Awh, E., Smith, E., & Jonides, J. (1995). Human rehearsal processes and the frontal lobes: PET evidence. *Annals of the New York Academy of Sciences*, 769, 97–117.
- Baddeley, A. (1996). The fractionation of working memory. *Proceedings of the National Academy of Sciences, USA*, 93, 13468–13472.
- Baddeley, A. (2000). The episodic buffer: A new component of working memory? *Trends in Cognitive Sciences*, 4, 417–423.
- Baddeley, A., & Hitch, G. (1974). Working memory. In G. A. Bower (Ed.), *The psychology of learning and motivation* (pp. 47–89). San Diego, CA: Academic Press.
- Baddeley, A., & Hitch, G. (1994). Developments in the concept of working memory. *Neuropsychology*, 8, 485–493.
- Baldo, J. V., & Dronkers, N. F. (2006). *Role of semantics in verbal working memory performance: Evidence from conduction aphasia*. Manuscript submitted for publication.
- Baldo, J. V., & Shimamura, A. P. (2000). Spatial and color working memory in patients with lateral prefrontal cortex lesions. *Psychobiology*, 28, 156–167.
- Baldo, J. V., Wilkins, D., & Dronkers, N. F. (2006). Working memory and language comprehension in patients with inferior parietal and inferior frontal lesions [Abstract]. *International Neuropsychological Society*, 12(Suppl. 1), 173.
- Becker, J. T., MacAndrew, D. K., & Fiez, J. A. (1999). A comment on the functional localization of the phonological storage subsystem of working memory. *Brain and Cognition*, 41, 27–38.

- Belleville, S., Peretz, I., & Arguin, M. (1992). Contribution of articulatory rehearsal to short-term memory: Evidence from a case of selective disruption. *Brain and Language*, *43*, 713–746.
- Chao, L., & Knight, R. (1995). Human prefrontal lesions increase distractibility to irrelevant sensory inputs. *NeuroReport*, *6*, 45–50.
- Chein, J. M., & Fiez, J. A. (2001). Dissociation of verbal working memory system components using a delayed serial recall task. *Cerebral Cortex*, *11*, 1003–1014.
- Chein, J. M., Ravizza, S. M., & Fiez, J. A. (2003). Using neuroimaging to evaluate models of working memory and their implications for language processing. *Journal of Neurolinguistics*, *16*, 315–339.
- D'Esposito, M., & Postle, B. R. (1999). The dependence of span and delayed-response performance on prefrontal cortex. *Neuropsychologia*, *37*, 1303–1315.
- Dronkers, N. F., Redfern, B., & Ludy, C. (1998). Brain regions associated with conduction aphasia and echoic rehearsal. *Journal of the International Neuropsychological Society*, *4*, 23–24.
- Dronkers, N. F., Wilkins, D. P., Van Valin, R. D., Jr., Redfern, B. B., & Jaeger, J. J. (2004). Exploring brain areas involved in language comprehension using a new method of lesion analysis. *Cognition*, *92*, 145–177.
- Gathercole, S. (1994). Neuropsychology and working memory: A review. *Neuropsychology*, *8*, 494–505.
- Gruber, O. (2001). Effects of domain-specific interference on brain activation associated with verbal working memory task performance. *Cerebral Cortex*, *11*, 1047–1055.
- Henson, R. N., Burgess, N., & Frith, C. D. (2000). Recoding, storage, rehearsal and grouping in verbal short-term memory: An fMRI study. *Neuropsychologia*, *38*, 426–440.
- Hickok, G., Buchsbaum, B., Humphries, C., & Muftuler, T. (2003). Auditory-motor integration revealed by fMRI: Speech, music, and working memory in area Spt. *Journal of Cognitive Neuroscience*, *15*, 673–682.
- Honey, G. D., Bullmore, E. T., & Sharma, T. (2000). Prolonged reaction time to a verbal working memory task predicts increased power of posterior parietal cortical activation. *NeuroImage*, *12*, 495–503.
- Jonides, J., Schumacher, E. H., Smith, E. E., Koeppe, R. A., Awh, E., Reuter-Lorenz, P. A., et al. (1998). The role of parietal cortex in verbal working memory. *Journal of Neuroscience*, *18*, 5026–5034.
- Kertesz, A. (1982). *Western Aphasia Battery*. New York: Grune & Stratton.
- Martin, N., & Saffran, E. (1997). Language and auditory-verbal short-term memory impairments: Evidence for common underlying processes. *Cognitive Neuropsychology*, *14*, 641–682.
- Paulesu, E., Frith, C., & Frackowiak, D. (1993, March 25). The neural correlates of the verbal component of working memory. *Nature*, *362*, 342–345.
- Postle, B. R., Berger, J. S., & D'Esposito, M. (1999). Functional neuro-anatomical double dissociation of mnemonic and executive control processes contributing to working memory performance. *Proceedings of the National Academy of Sciences, USA*, *96*, 12959–12964.
- Ravizza, S. M., Delgado, M. R., Chein, J. M., Becker, J. T., & Fiez, J. A. (2004). Functional dissociations within the inferior parietal cortex in verbal working memory. *NeuroImage*, *22*, 562–573.
- Rorden, C., & Brett, M. (2000). Stereotaxic display of brain lesions. *Behavioural Neurology*, *12*, 191–200.
- Saffran, E., & Martin, N. (1990). Neuropsychological evidence for lexical involvement in short-term memory. In G. Vallar & T. Shallice (Eds.), *Neuropsychological impairments of short-term memory* (pp. 145–166). Cambridge, England: Cambridge University Press.
- Salmon, E., Van der Linden, M., Collette, F., Delfiore, G., Maquet, P., Degueldre, C., et al. (1996). Regional brain activity during working memory tasks. *Brain*, *119*, 1617–1625.
- Shallice, T., & Butterworth, B. (1977). Short-term memory impairment and spontaneous speech. *Neuropsychologia*, *15*, 729–735.
- Shallice, T., & Vallar, G. (1990). The impairment of auditory-verbal short-term storage. In G. Vallar & T. Shallice (Eds.), *Neuropsychological impairments of short-term memory* (pp. 11–53). Cambridge, England: Cambridge University Press.
- Shallice, T., & Warrington, E. (1977). Auditory-verbal short-term memory impairment and conduction aphasia. *Brain and Language*, *4*, 479–491.
- Vallar, G., & Baddeley, A. (1984). Phonological short-term store, phonological and sentence comprehension: A neuropsychological case study. *Cognitive Neuropsychology*, *1*, 121–141.
- Vallar, G., Di Betta, A. M., & Silveri, C. (1997). The phonological short-term store-rehearsal system: Patterns of impairment and neural correlates. *Neuropsychologia*, *35*, 795–812.
- Vallar, G., & Papagno, C. (2002). Neuropsychological impairments of verbal short-term memory. In A. Baddeley, B. Wilson, & M. Kopelman (Eds.), *Handbook of memory disorders* (2nd ed., pp. 249–270). Chichester, England: Wiley.
- Warrington, E. K., Logue, V., & Pratt, R. T. (1971). The anatomical localization of selective impairment of auditory verbal short-term memory. *Neuropsychologia*, *9*, 377–387.
- Warrington, E. K., & Shallice, T. (1969). The selective impairment of auditory verbal short-term memory. *Brain*, *92*, 885–896.
- Wilson, M. (1988). The MRC Psycholinguistic Database: Machine Readable Dictionary, Version 2. *Behavioural Research Methods, Instruments, and Computers*, *20*, 6–11.

Received September 29, 2005

Revision received April 20, 2006

Accepted April 26, 2006 ■